

Dumbell Shaped C1-C2 Schwannoma- A Case Report

Durga Prasad Bukka¹, Vishal Chakati¹, Srinivas Rao E², Shivanand Reddy², Shyam Sunder Anchuri³

¹ Pharm D Interns
Department of
Pharmacy Practice
Balaji Institute of
Pharmaceutical Sciences
Laknepally(V),
Warangal(DT)-506331
² Consultant of Neuro Surgeons
Srinivasa Pinnacle Neuro
& Multispeciality Hospital
Hanamkonda
Warangal-506001
³ Professor and Head
Department of
Pharmacy Practice
Balaji Institute of
Pharmaceutical Sciences (BIPS)
Laknepally,
Warangal Rural-506331
Telangana, India.
E-mail:
bdurgaprasad15071998@gmail.com

ABSTRACT

Patients with C1-C2 dumbbell shaped cervical nerve root schwannomas approach to the hospital with common clinical presentations of neck or head pain and radiating pain up to the back and head. A 57-year-old female was referred to neuro care center in view of a slow-growing lump in the left sided posterosuperior aspect of the neck since 20 years. The lump was asymptomatic. Radiological examinations done, Magnetic resonance imaging revealed probably neurofibroma/schwannoma, C1-C2 level extending from spinal canal through neural foramina into left para spinal soft tissue, at C2 level the lesion causing mass effect over cord. Related biopsies of the lesion showed spindle cells arranged in bundles with nuclear palisading Verucay bodies consistent with a schwannoma. The lesion was surgically excised by left sided far lateral approach.

Keywords: Schwannoma, cervical root, dumbbell, lateral, neurofibroma

CORRESPONDENCE:

Dr. A. Shyam Sunder,
M. Pharm, Ph.D
Professor and Head
Department of
Pharmacy Practice
Balaji Institute of
Pharmaceutical Sciences (BIPS)
Laknepally,
Warangal Rural-506331
Telangana, India.
E-mail: shyamar9@gmail.com

INTRODUCTION

The incidence rate of spinal cord tumors is 1.1 per 100,000 population.^[1] Upper cervical nerve peripheral nerve sheath tumors (PNSTs) composed of schwannomas and neurofibromas arise commonly from the second cervical(C2) root and rarely from the first cervical(C1) root.^[2] They can grow without any symptoms to a large size and extend via intervertebral foramina to form a dumbbell shape and typically present with signs relating either directly to C1-C2 nerve dysfunction or compression

of adjacent structures like spinal cord and vertebrobasilar arterial system.^[3,4]

CASE REPORT

A 57 year old house wife, with previous medical history of diabetes mellitus since 5 years and hypertension since 15 years, was referred to the neuro care center in view of slow growing lump over left posterosuperior aspect of the neck. It had been growing slowly since 20 years; she was asymptomatic and not experienced any pain, skin

changes or any other neurological symptoms. Neurological and general systemic examinations were unremarkable and blood investigations were normal. For identification and characterization of lesion magnetic resonance imaging (MRI) of the cervical spine contrast (Fig-1) was done. This showed a lobulated altered signal intensity lesion measuring 56x37 mm at C1-C2 level extending from spinal canal through neural foramina into left para spinal soft tissue. The lesion is hypo on T2, hyper on STIR and hypo on T1 with intense homogeneous enhancing in post contrast series. At C2 level the lesion

causing mass effect over cord.

Computed tomographic (CT) neck angiography (Fig-2) performed. This showed a lobulated minimally enhancing soft tissue dense mass of size 44x53x40 mm (APxTRxCC) noted at C1 and C2 level on left side causing erosion of vertebra. The lesion is infiltrating left vertebral artery and showing intra-spinal extension-likely neurogenic tumor. Rest of the left vertebral arteries showing small in calibre with minimal post contrast enhancement.




Figure 1: MRI Cervical Spine Contrast- showing lobulated altered signal intensity lesion measuring 56x37mm at C1-C2 level extending from spinal canal through neural foramina into left para spinal soft tissue. The lesion is hypo on T2, hyper on STIR and hypo on T1 with intense homogenous enhancing in post contrast series. At C2 level the lesion causing mass effect over cord.

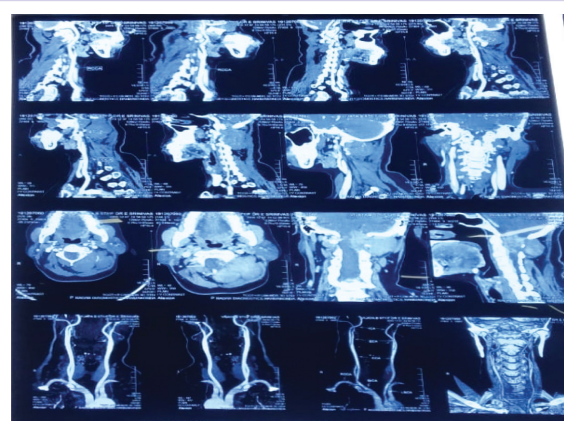


Figure 2: CT Neck Angiography- showing lobulated minimally enhancing soft tissue dense mass of size 44x53x40mm (APxTRxCC) noted at C1 and C2 level on left side causing erosion of C1 vertebra. The lesion is infiltrating left vertebral artery and showing intra-spinal extension. Rest of the left vertebral artery showing small in caliber with minimal post contrast enhancement.

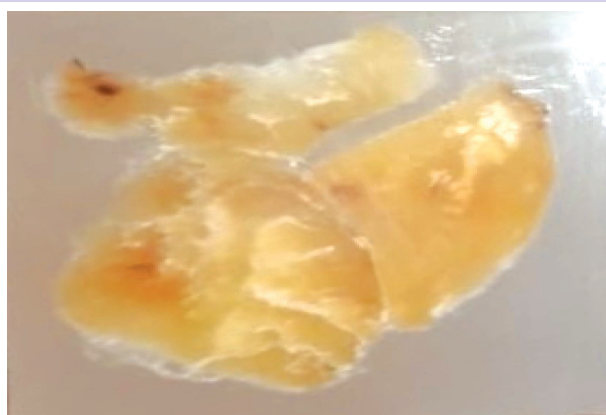


Figure-3: Biopsy Report- Gross appearance revealed multiple soft tissue bits largest 5cm, smallest 2cm. Microscopic appearance revealed tumor tissue comprised or spindle cells arranged in bundles with nuclear palisading verucacy bodies.

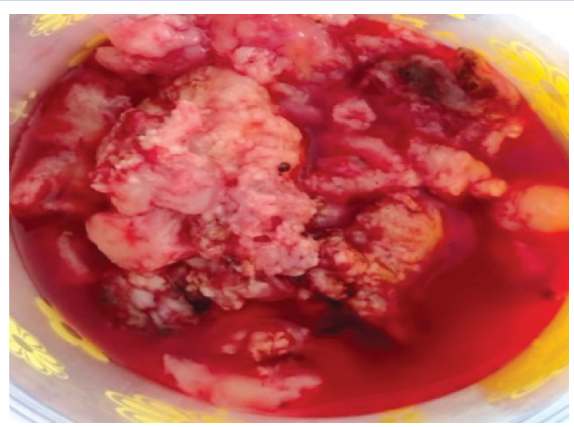


Figure-4: An image of surgically removed tumor

Histological Examination

Stereotactic biopsies of the lesion (Figure-3) showed: gross appearance- revealed multiple soft tissue bits largest 5 cm, smallest 2cm, c/s grayish white, slimy. Microscopic appearance- revealed tumour tissue comprised of spindle cells arranged in bundles with nuclear palisading Verucay bodies. These features are consistent with diagnosis of a schwannoma.

Surgical procedure

The patient agreed to undergo removal of the schwannoma. The operative, tumor identified over the C1 and C2 regions and removed as piecemeal (Figure-4) and compression over the sac is identified and removed. Dural evagination on the left side below the foramen magnum noted, dura opened to look for any intradural negativity but no negativity is noted and after achieving hemostasis closure done in layers.

Postoperative recovery was unremarkable. A review conducted after 4 weeks of plan included a left sided far lateral approach for complete removal of the lesion. The procedure was performed under general anesthesia, with the patient prone. A T-shaped incision was performed over the posterior region of the neck, and opened in layers the procedure did not reveal any complications.

DISCUSSION

Schwannomas are benign neoplasms that originate from Schwann cells surrounding peripheral nerves. They form part of a larger category of tumors' referred to as peripheral nerve sheath tumors.^[5]

Schwannomas are usually solitary lesions, and can arise from any peripheral nerve, often originating from the sensory nerve roots, with motor and autonomic nerves being less frequently involved. Rarely, schwannomas can

arise from brain, spinal cord or gastrointestinal parenchyma.^[6] They are most commonly observed in patients between the ages of 20 and 50 years, in a roughly equal gender distribution.^[5,6]

The pathogenesis behind schwannomas is incompletely understood and most cases tend to be sporadic in nature. However, several genetic syndromes are associated with the formation of schwannomas. Neurofibromatosis Type 2, which is caused by point mutations in the NF2 gene and is associated with the formation of unilateral or bilateral neuromas of the vestibular nerve.^[6]

Conversely, schwannomatosis, which is associated with mutations in the SMARCB1 gene, results in the formation of numerous peripheral, often painful, schwannomas, affecting the neck, trunk and extremities.^[7] The Carney complex, which is caused by an autosomal dominant mutation in the PRKAR1A gene and it is associated with the formation of atrial myxomas, lentiginos, blue nevi and myxoid schwannomas that often affect the upper gastrointestinal tract and sympathetic chains.^[8]

Schwannoma arising from upper cervical spinal (C1,C2,C3) roots are commoner than any other spinal nerves.^[9] This type of schwannoma may be intradural, extradural or hourglass form (intra and extradural).^[10]

Schwannomas arising from the C1 spinal nerve tumors are extremely rare because it is not supplied with sensory root and C2 spinal nerve tumors are common and exhibit a high prevalence of dumbbell morphology because the space between the lamina is wide at C1/C2, a spinal cord tumor might progress out of the spinal canal more easily than tumors at other levels, where it is supplied with sensory neurons.^[2,3,8,11,12,13]

This article is of both intra and extradural type of schwannoma commonly referred as dumbbell shaped schwannoma rare type. The management of this tumor tends to be complex, varied and case specific. Overall a far lateral approach is used to remove the lesion.

CONCLUSION

Dumbbell shaped C1 and C2 schwannoma is a benign tumor. Gross total removal of tumor is achieved with good clinical outcome and with minimal risks.

CONFLICT OF INTEREST:

The authors declared no conflict of interest.

FUNDING: None

REFERENCES

1. Louis DN, Ohgaki H, Wiestler OD, Cavenee WK, Burger PC, Jouvet A et al. The 2007 WHO Classification of Tumours of the Central Nervous System. *Acta Neuropathol.* 2007; 114(2):97-109.

2. Hovorka MS, Uray NJ. Microscopic clusters of sensory neurons in C1 spinal nerve roots and in the C1 level of the spinal accessory nerve in adult humans. *Anat Rec (Hoboken)*. 2013; 296:1588-93.
3. Goel A, Muzumdar D, Nadkarni T, Desai K, Dange N, Chagla A. Retrospective analysis of peripheral nerve sheath tumors of the second cervical nerve root in 60 surgically treated patients. *J Neurosurg Spine*. 2008; 8(2):129-134.
4. El-Sissy MH, Mahmoud M. C2 root nerve sheath tumors management. *Acta Neurochir (Wien)*. (2013); 155(5):779-784.
5. Rodriguez FJ, Folpe AL, Giannini C, Perry A. Pathology of peripheral nerve sheath tumors: diagnostic overview and update on selected diagnostic problems. *Acta Neuropathol*. 2012; 123:295-319.
6. Hilton DA, Hanemann CO. Schwannomas and their pathogenesis. *Brain Pathol*. 2014; 24:205-220.
7. Ioannidis P, Mamouli D, Foroglou N. Expanding schwannomatosis phenotype. *J Neurooncol*. 2015; 122:607-609.
8. Kyoshima K, Uehara T, Koyama J, Idomari K, Yomo S: Dumbbell C2 schwannomas involving both sensory and motor rootlets: report of two cases. *Neuro Surg*. 2003; 53:436-440.
9. Belzberg AJ, Campbell JN. Neoplasms of the peripheral nerves. *Neuro Surg*. 1996; 2:3217-3223.
10. Chowdhury FH, Haque MR, Sarker MH. High cervical spinal schwannoma; microneurosurgical management: an experience of 15 cases. *Acta Neurol Taiwan*. 2013; 22:59-66.
11. Watanabe M, Sakai D, Yamamoto Y, Iwashina Y, Sato M, Mochida J. Upper cervical spinal cord tumors: review of 13 cases. *J Orthop. Sci*. 2009; 14(2):175-181.
12. Sato M, Takemitsu Y, Iwahara T, Ozawa K, Atsuta Y, Muramoto T. Three cases of spinal cord tumor originating from the second cervical nerve root. *J Spinal Disord*. 1998; 11(4):354-358.
13. Krishnan P, Behari S, Banerji D, Mehrotra N, Chhabra DK, Jain VK. Surgical approach to C1-C2 nerve sheath tumors. *Neurol. India*. 2004; 52(3):319-324.