

Mammographic and Sonographic Evaluation of Breast Masses: A Comparative Study

Santhosh Babu R¹, Naveen Kumar S², Anil Kumar S³, Mahesh Ch⁴

¹ Professor & Head

² Associate Professor

^{3,4} Postgraduate Student

Department of Radiology
Chalmeda Anand Rao
Institute of Medical Sciences
Karimnagar-505001
Telangana, India.

CORRESPONDENCE:

Dr. S. Naveen Kumar,
MD (Radio-Diagnosis)
Associate Professor
Department of radio-Diagnosis
Chalmeda Anand Rao
Institute of Medical Sciences
Karimnagar-505001
Telangana, India.
E-mail: kodisiripuram@gmail.com

ABSTRACT

Background and Aims: Breast lump is the clinical presentation of various breast diseases that range from benign cyst to malignant lesions. Differentiation of benign from malignant is the most important aspect for patient care and proper management. The Aim and objectives was 1). To study the mammographic and sonographic characteristics of the breast lesions. 2). To study the sensitivity of combined mammography and ultrasound compared to that of individual modalities in diagnosing malignant lesions of the breast 3). To compare results the present study with similar studies available in the present literature

Materials and Methods: This is a prospective study done on 60 patients over a period of 18 months in Department of Radio Diagnosis, Chalmeda Anand Rao Institute of Medical Sciences, Karimnagar.

Results: In present comparative study in 60 solid masses Diagnosing palpable breast masses by mammography alone. Benign cases were 19, Malignant cases were 26, Suspicious cases were 15 Diagnosing benign/malignant tumour by mammography alone was Sensitivity 89%, Specificity 94%, Positive predictive value 92% Negative predictive value 91% values. Our sample size for the study was fairly small compared to many of the other studies referred to for comparison. Also, we have considered only those masses that were palpable. Hence, there may be a slight variation in the results and percentages.

Conclusion: In present comparative study diagnosing benign/malignant cases by mammography alone has sensitivity 89% positive predictive value 92%. Diagnosing Benign /malignant cases by sonography alone has sensitivity 92% positive predictive value 92%. Diagnosing benign /malignant cases by combined sonography & mammography has increased sensitivity & positive predictive values up to 100% & 100% respectively which indicates combined study is better than individual alone studies. Hence it can be concluded that combined mammography and high resolution ultrasound yields highest diagnostic accuracy in evaluating palpable breast lesions, especially in relatively young patients or in radiologically dense breasts.

Keywords: Mammography, sonography, breast lesions.

INTRODUCTION

Breast lumps are common problem affecting females, which require proper workup, early diagnosis and treatment. Mammography is used as both screening modality and as efficient technique to evaluate clinically suspected breast lesions. High resolution sonography is a adjunct modality used in detecting lesions in dense breast and supplementary assessment of breast lesions.

MATERIALS AND METHODS

This is a prospective study done on 60 patients over a

period of 18 months in Department of Radio Diagnosis Chalmeda anand Rao Institute of Medical Sciences, Karimnagar.

Inclusion criteria:

- Women with palpable breast lumps
- Pain, and nipple discharge

Exclusion criteria:

- Women with advanced malignancy
- Fungating mass per breast
- Mass adherent to chest wall

- Pregnant women
- All patients had routine Clinical examination, Mammography and Sonomammography of both the breasts.
- Sonomammography was performed, with a 7.5-10 MHz Linear array Transducer (Philips affinity 70)
- Both the breast were scan radially and by grid scanning technique.
- A thorough ultrasound examination was performed in Sagittal plane, Transverse plane, Radial plane.
- Mammography was performed using a dedicated Mammography unit (Siemens).
- A Kilovoltage Peak (kVp) setting of 26-29 is commonly used for breast of average size and density with focal spot of 0.4 mm using a target and filter of Molybdenum.
- Cranio-caudal and Medio-lateral views of both the breasts were performed after adequate compression.

Ethics Approval

The study was reviewed and approved by the Institute Ethics Committee, Chalmeda Anand Rao Institute of Medical Sciences, Karimnagar.

STATISTICAL ANALYSIS

Diagnostic accuracy was calculated in terms of sensitivity, specificity, positive predictive value, negative predictive value for mammography, sonography individually and in combination. Both descriptive and inferential statistics were employed for data analysis.

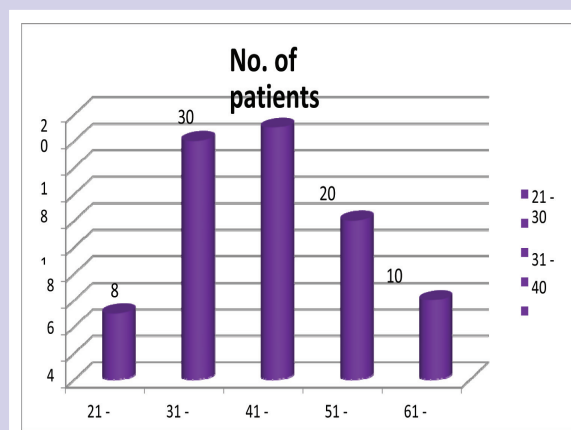
OBSERVATIONS AND RESULTS

Table 1: Number of Palpable Abnormalities after Combined Mammographic And Sonographic Evaluation

Imaging Findings	No. of Palpable Abnormalities
Benign	14
Suspicious	22
Malignant	24

Table 1 Distribution of Patients in specific Age group

S.No.	Age group (n)	No. of Patients (N)	Percentage (%)
1	21-30	5	8%
2	31-40	18	30%
3	41-50	19	32%
4	51-60	12	20%
5	61-81	6	10%



Graph 1: Distribution of patients in specific age group

X-Axis = Number of patients.

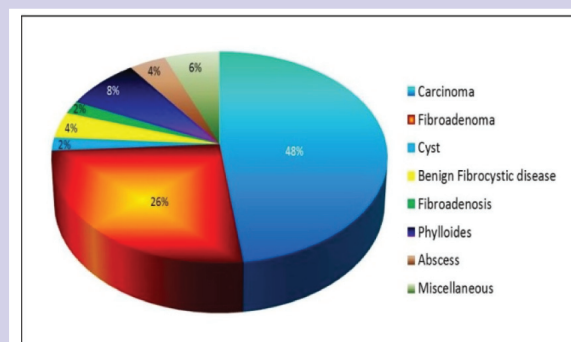
Y-Axis. Age group. Age distribution of palpable breast masses.

Table 2 Percentage and Number of specific palpable abnormalities in total palpable Abnormalities

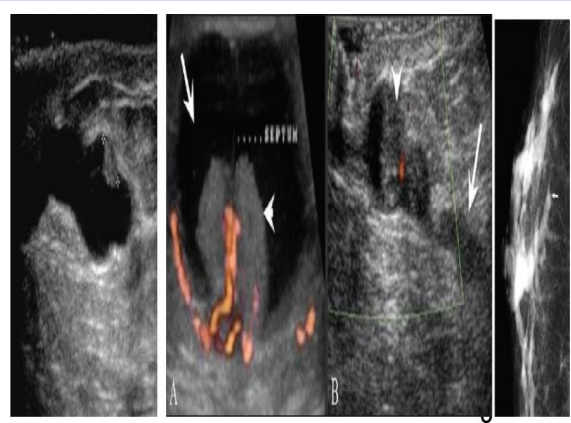
S.No.	Lesion	No. of Patients	Percentage (%)
1	Carcinoma	29	48%
2	Fibroadenoma	16	26%
3	Cyst	1	2%
	Benign		
	Fibrocystic		
	Disease	2	4%
5	Fibroadenosis	1	2%
6	Phylloides	5	8%
7	Abscess	2	4%
8	Miscellaneous	4	6%

n =Number of cases

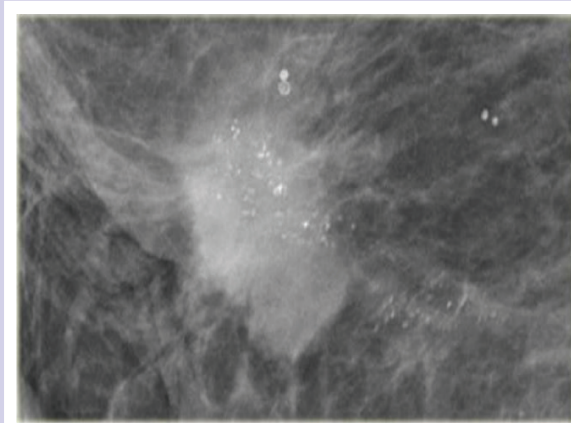
N = Total number of cases




Graph 2: Percentage and number of specific palpable abnormalities in total palpable abnormalities



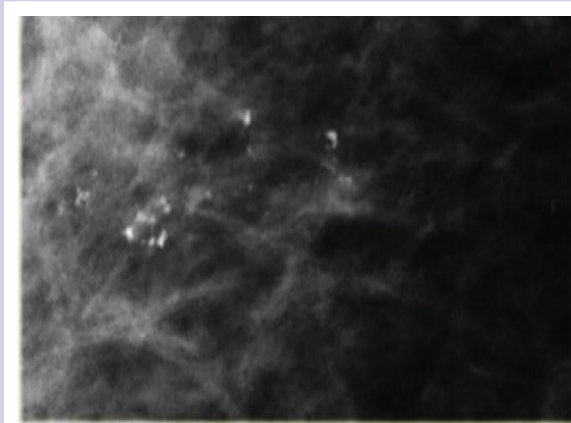
Papilloma




Fine Pleomorphic calcifications in a segmental distribution



Fine pleomorphic calcification in a linear distribution



Amorphous calcification



Coarse heterogeneous Microcalcification

Table 2 and Graph shows breast lesions as follows: Carcinoma in 29 patients, Fibroadenoma in 16 patients, Cyst in one patient, benign fibrocystic disease in 2 patients, Fibroadenosis in one patient, phylloides in 5

patients, abscess in 2 patients and miscellaneous in 4 patients.

DISCUSSION

Breast carcinoma is less common in woman less than 40 years of age. Mammography has lower sensitivity in younger women because of dense breast parenchyma. It had been detected in only 4% of cases with pathological abnormalities of breast.

Benign Lesions of the Breast

Cysts are in turn described in the group of fibrocystic mastitis, which present as palpable swellings. On ultrasound, cysts appear as well defined anechoic smooth walled, oval or round lesions showing posterior acoustic enhancement.

On mammography, a cyst reveals features of lump with smooth margins. Sometimes cysts are showing loss of delineated margins because they are embedded in dense fibrous tissue.^[1]

Cysts

Cysts are round or ovoid structures which are filled with fluid mostly found in age group between 30-50 year age group. Most of them are subclinical/ "micro cysts," in 20%–25% of cases, palpable (gross) cystic change, which usually presents as a simple cyst. Hence ultrasound is the modality of choice in differentiating solid and cystic lesions of the breast. It is superior to mammography because of its 100% sensitivity and specificity in cystic lesions of the breast.

Infective Pathology:

Breast abscess in mammography appear as an ill defined mass with speculated margins which mimic carcinoma and in ultrasound abscesses having internal echoes with irregular contour with ill defined shape.

On a mammogram, a breast abscess appears as a poorly defined mass or a mass with spiculated borders simulating a carcinoma. On USG, most abscesses presented with ill defined shape and have poorly defined contours with thin internal echoes..

Intraductal papilloma

Intraductal papilloma is a benign tumour arising from the mammary duct epithelium. It may develop at any site in the ductal system and shows a propensity towards terminal ductules and sinuses.

Fibroadenoma

It is the 3rd most common breast lesion that usually occurs in adolescence which is an estrogen induced tumour & usually presents as a non tender, firm, smooth, freely mobile in all directions, oval-shaped. These are usually single, unilateral and size < 5 cm, multiple in 10-20% and bilateral in 4% of cases.

Calcifications may occur. On USG, it appears as a well-defined, homogenous and hypo echoic lesion and capsule can be identified. With low-level internal echoes.

Typically antero posterior diameter is lesser than the transverse diameter. In some patients the mass may be complex, iso echoic or hyper echoic. Similarly USG appearance may be seen with papillary carcinoma, medullary or mucinous. 56.4% fibro adenosis constitute 20.9%.

Fibrocystic disease

Synonyms

1. Fibrocystic disease
2. Fibrocystic change
3. Cystic disease

4. Chronic cystic mastitis or
5. Mammary dysplasia.

On USG it can be variable because it depends on extensive morphological changes and stage. the USG appearance in early changes it can be normal, though lumps can be palpable on clinical examination. Focal areas of thickening of the parenchyma may shows patchy increase in echogenicity Single sub centi metric discrete cysts or of small cyst arranged in clusters can be seen.

Focal fibrocystic changes can seen as solid masses or cysts with thinned walls. these are usually classified as indeterminate and further require biopsy. Predominant cystic nature seen on the mammogram as a dense breast or ill- defined multiple masses. On a USG, multiple cysts of varying sizes are seen.

Malignant Lesions of the Breast

Mouchawar J et al ^[43] In the Denver Metropolitan area in Colorado, 240,000 women registered in a mammography screening program. genetic testing awareness was there which in turn gives the information of association with presence of family history, increasing from 35% to 67% from the lowest family history risk group to highest familial history.

The first sign is of very fine linear opacities present across the subcutaneous tissue along the skin: these are due to dilated lymphatic reaction, in these small blood vessels are detected in increased opacities.

Increasing severity of reaction will lead to an increased opacities and blood vessels and also to an increase in diameter With increasing severity the echogenicity of the deep surface of the skin varies, and in cases with a minimal reaction, the deep surface is clearly demarcated from the underlying fat tissue As the severity increases thorn'-like projections could be seen into the fat from the skin.

A subcutaneous reaction was never seen in benign lesions, as in fibro adenomas or simple cysts, unless any recent procedure like Tru-cut needle biopsy or cyst aspiration had been performed.

The appearance of a reaction in patients with benign lesions who were analysed earlier after needling would show to false positive features of malignancy Infection would results in to a reaction which may be localised.

In a low-grade abscess, it could be generalised and also a more diffuse infective mastitis. Diagnosis of malignancy can be made by absence of infection or needling and need to be evaluated further with biopsy. The absence of the sign does not exclude the malignant feature, especially in the case of mucoid or medullary cell carcinoma. If the

subcutaneous reaction was severe and if associated with skin thickening it can be valuable feature in differentiating benign mass and malignant mass. If it was used as a solitary indication of malignancy, 96% sensitivity was detected. Subcutaneous retraction was also observed in abscesses and focal fibrosis.

Breast ultrasound: criteria for benign lesions

Several articles have analysed the sonographic characteristics commonly seen in benign lesions of the breast:

1. Smooth margins and well circumscribed
2. Hyper echogenic, iso echogenic or mildly hypo echogenic
3. Thin capsule with echogenic margins
4. Ellipsoid shape, with breadth more than length.
5. Absence of malignant features

Characteristics of malignant lesions

Malignant lesions are usually hypo echogenic lesions with ill-defined borders. Typically, a malignant lesion appears as a

- hypo echogenic nodular lesion, which is having length more than breadth.
- Margins are spiculated
- Posterior acoustic shadowing and Micro calcifications

Fine Pleomorphic calcification in a segmental distribution
Malignant calcifications are typically pleomorphic or heterogeneous and appear as linear, branching, irregular or granular forms depend on the lesion. Fine pleomorphic calcification in a Linear distribution Amorphous calcification Coarse heterogenous Microcalcification

CONCLUSION

In present study, there was no significant difference in sensitivity between Mammography and USG ($p=0.3768$) but there was significant difference mammography alone and MG-USG combination ($p=0.0015$) and USG alone and USG-MG combination ($p=0.0001$).

Hence it can be concluded that combined mammography and high resolution ultrasound yields highest diagnostic accuracy in evaluating palpable breast lesions, especially in relatively young patients or in radiologically dense breasts.

CONFLICT OF INTEREST:

The authors declared no conflict of interest.

FUNDING: None

REFERENCES

1. Shetty MK, Shah YP, Sharman RS. Prospective evaluation of value of combined mammographic and sonographic assessment in patients with palpable abnormalities of breast. *J Ultrasound Med.* 2003; 22:263-268.
2. Gokhale S. Ultrasound characterization of breast masses. *Indian J Radiol Imaging.* 2009; 19:242-7.
3. Graf O, Helbich TH, Fuchsjaeger MH, Hopf G, Morgun, M, Graf C, Sickles, E.A. Follow-up of Palpable Circumscribed Noncalcified Solid Breast Masses at Mammography and US: *Can Biopsy Be Averted Radiology.* 2004; 233(3):850-856.
4. David Lieu. Breast Imaging for Interventional Pathologists. *Archives of Pathol Laboratory Med.* 2013; 137(1):100-11.
5. McCormack V, Dos Santos Silva I. Breast density and parenchymal patterns as markers of breast cancer risk: a meta-analysis. *Cancer Epidemiol Biomarkers Prevention.* 2006; 15:1159-1169.
6. Prasad SN and D. Houserokova. A Comparison of Mammography and Ultrasonography in the Evaluation of breast masses. *Biomedical Papers of the Medical Faculty of the University Palacky, Olomouc, Czech Republic.* 2007; 151(2):315-322.
7. Kelly KM, Dean J, Comulada WS, Lee SJ. Breast cancer detection using automated whole breast ultrasound and mammography in radiographically dense breasts. *Eur Radiol.* 2010; 20(3):734-742.
8. Martin L, Boyd N. Potentials mechanisms of breast cancer risk associated with mammographic density: hypotheses based on epidemiological evidence. *Breast Cancer Res.* 2008; 10:20.
9. Patumanond J, Kayee T, Sukkasem U. Empirical accuracy of fine needle aspiration cytology (FNAC) for preoperative diagnoses of malignant breast lumps in hospitals with restricted health resources. *Eur J Gynaecol Oncol.* 2009; 30(3):295-299.
10. Zimmermann N, Ohlinger R. Diagnostic value of palpation, mammography, and ultrasonography in the diagnosis of fibroadenoma: impact of breast density, patient age, ultrasonographic size, and palpability. *Ultraschall in der Medizin.* 2021; 33(7):151-157.
11. Wishart GC, Warwick J, Pitsinis V, Duffy S, Britton PD. Measuring performance in clinical breast examination. *Br J Surg.* 2010; 97(8):1246-1252.
12. Dromain C, Thibault F, Diekmann F et al. Dual-energy contrast-enhanced digital mammography: initial clinical results of a multireader, multi case study. *Breast Cancer Res.* 2012; 14(3):R94.
13. Heine JJ, Fowler EE, Flowers CI. Full field digital mammography and breast density: comparison of calibrated and noncalibrated measurements. *Acad Radiol.* 2011; 18(11):1430-1436.
14. Abhijit MG, Anantharaman D, Sumanth Bhoopal, Ranjani Ramanujam: Benign breast diseases: experience at a teaching hospital in rural India. *IJRMS.* 2013; 1(2):73-78.
15. Aisha Memon, Shahida Parveen, AK. Sangrarasi, Arshad M. Malik, Aziz Laghari and K. Altaf Hussain Talpur. Changing Pattern of benign breast lumps in young females. *World J Med Sci.* 2007; 2 (1):21-24.
16. Muhammad Naeem, Nadim Khan, Zahid Aman, Amir Nasir, Ambreen Samad, Abbas Khatta. Pattern of breast cancer: experience at lady reading Hospital, Peshawar. *J Ayub Med Coll Abbottabad.* 2008; 20(4):22-5.
17. Parate R, Kasat V, Solanke R. Evaluation of breast masses using

- mammography, sonography and its correlation. *J Evolution Med Dent Sci*. 2018; 7(23):2823-2828.
18. Tiwari P, Ghosh S, Agrawal VK. Evaluation of breast lesions by digital mammography and ultrasound along with fine-needle aspiration cytology correlation. *J Can Res Ther*. 2018; 14:1071-4.
19. Jaipal R Beerappa, Balu S, Nandan Kumar LD, Anuradha Kapali, Raghuram P. Mammographic and sonomammographic evaluation of breast masses with pathological correlation: a prospective original study. *Int J Anat Radiol Surg*. 2016; 5(3):09-12.