

Lymphangioma of Neck in a 35-year Old Female: A Case Report of Rare Entity

Ramesh Kumar S¹, Jadi Lingaiah², Manoj Gunde³, Cheeti Apparna⁴

¹ Retired Professor & HOD

² Professor

³ PG Student

⁴ Resident

Department of
Otorhinolaryngology
& Head and Neck Surgery
Chalmeda Anand Rao
Institute of medical sciences
Karimnagar, 505001
Telangana, India.

CORRESPONDENCE:

¹Dr. Jadi Lingaiah, MS(ENT)
Professor
Department of
Otorhinolaryngology
& Head and Neck Surgery
Chalmeda Anand Rao
Institute of medical sciences
Karimnagar, 505001
Telangana, India.
E-mail:drjadi_ms@yahoo.com

ABSTRACT

Lymphangiomas are lymphatic malformations which occur mostly in children and uncommonly in adult. Although the lesion can occur anywhere, the most common sites are in the posterior triangle of the neck, axilla, mediastinum, groin, retroperitoneal space and pelvis in a descending order.

We hereby report a rare case of a 35 years old woman with lymphangioma of neck who presented in ENT OPD with a slowly enlarging neck swelling on right side of 6 months duration for which excision was done after USG and FNAC and sent for HPE which was suggestive of lymphangioma. The adult lymphangioma which is unusual in occurrence, prompted us to report this case.

Keywords: lymphangioma, cystic hygroma, cavernous lymphangioma.

INTRODUCTION

Lymphangiomas refer to a group of developmental anomalies in which lymphatics fail to connect in the normal way to the venous channels. It is often presented as progressive and painless swelling. Mostly lymphangiomas are congenital.

The cause remains unknown in adults but they have been reported to arise from trauma, infections and iatrogenic injuries in an adult. Imaging techniques can help in defining its boundaries with the surrounding structures. Complete surgical excision is considered to be the best approach.

Mini Literature Review

Although a rare entity in adults few authors stated the similar lesions in adults. Nikita Rolekar et al found recurrent lymphangioma in a 35 year old female and stated that complete surgical excision will decrease the chance of recurrence.^[1]

A direct relation was observed between the extent of the lesion and the number of operations performed, rate of recurrence, and residual disease. Charabi et al emphasised that nonencapsulated lesions occur more frequently because of their tendency to infiltrate major neurovascular structures.^[2] Baer and Davis reported an

89-year old male patient with lymphangioma which is the oldest patient reported in the literature.^[3] Large series of patients were reported in mayo clinic where 32 patients were treated for lymphangioma.^[4]

CASE REPORT

A 35 years old woman presented in our hospital with swelling in right side of lateral aspect of lower neck for 6 months, which was initially small in size of 2 x 2 cm, gradually increased to present size of 5 x 3 cm. She had a complaint of slight discomfort in neck movement. She had no pain over swelling, shortness of breath, dysphagia and dysphonia with no other swellings in the body.

On clinical examination, swelling was soft, cystic, non-mobile, with no local raise of temperature situated in posterior triangle of neck which was present between

posterior border of sternocleidomastoid muscle and anterior border of trapezius muscle & measured 5 x 3 cm size with transillumination test positive. The swelling was non pulsatile with no dilated neck veins and trachea is centrally placed.

Differential Diagnosis

Based on the clinical findings the differential diagnosis were Cystic hygroma, Lipoma, Pharyngeal pouch, Subclavian aneurysm, Aberrant thyroid.

Investigations

Blood tests were normal. USG neck suggestive of 5 x 2.5 cm size ill-defined anechoic cystic lesion with multiple septation and loculation present in supraclavicular region extending up to right posterior triangle (Figure 1). CT

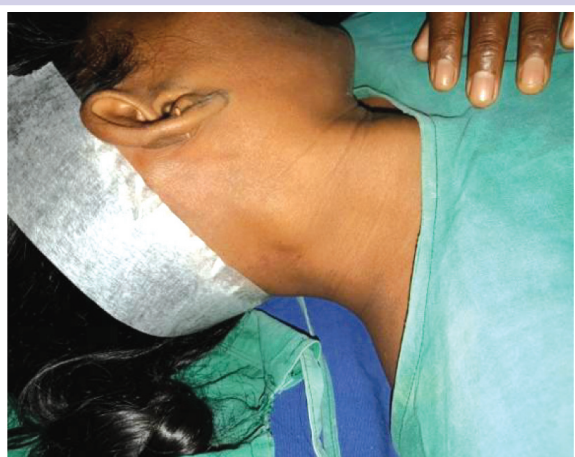

Figure 1: Macroscopic view of the cystic hygroma of the neck region.

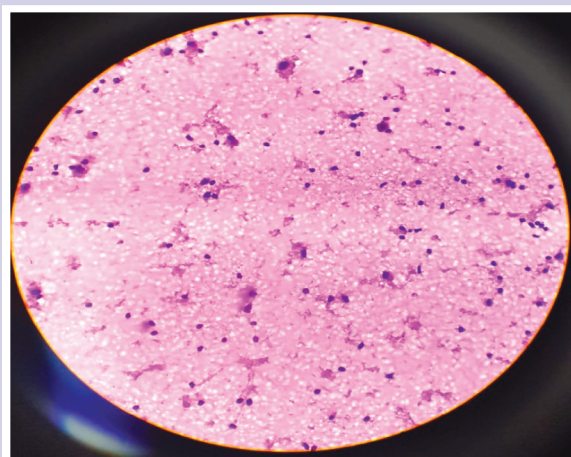


Figure 2: FNAC H&E stain - Smear shows cellular smear with numerous lymphocytes and few cyst macrophages.

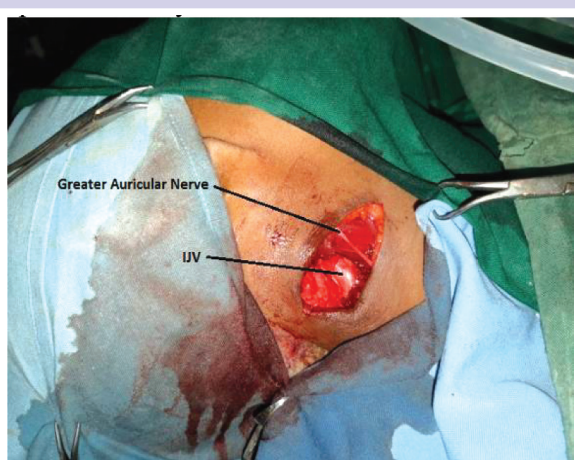


Figure 3: Intra operative macroscopic view after excision of cyst.

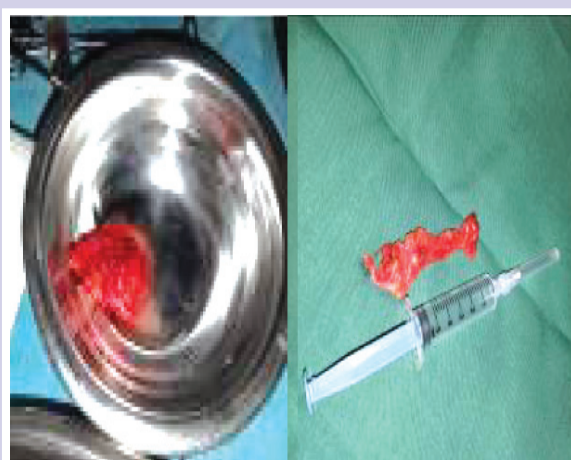


Figure 4: Postoperative gross appearance of the cyst after complete surgical excision.

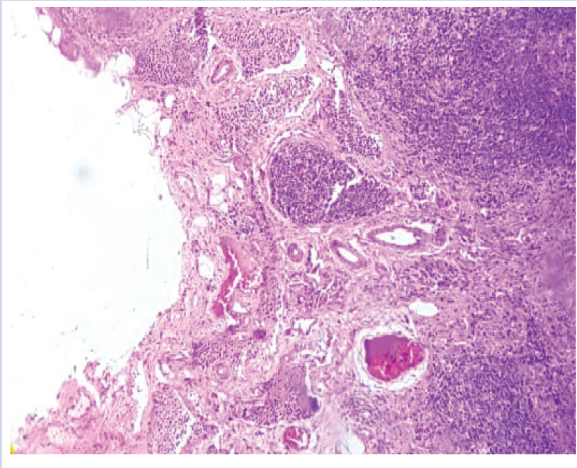


Figure 5: H&E staining showing fibrocollagenous tissue with cystically dilated spaces lined by flattened endothelium.

scan of neck revealed multiloculated cystic lesion of 54 x 24 mm size with thin peripheral wall and thin septation is noted in intermuscular and subcutaneous plane in posterior triangle of neck on right side. The lesion is located posteriolateral to right sternocleidomastoid muscle, lateral to right carotid and jugular vessel and right scalene muscle anterior to right trapezius muscle and posterosuperior to clavicle and subclavian vessel suggestive of possible lymphangioma. FNAC of the swelling shows cellular smear with numerous lymphocytes and few cyst macrophages seen against amorphous background which is suggestive of lymphangioma (Figure 2).

Treatment

After taking informed written consent, patient had been taken up for surgery. The swelling was approached with 6 cm transverse skin incision with 8cm above and parallel to upper border of clavicle.

A 5x2x2cm size cystic swelling was circumferentially dissected and removed in its entirety. The Care has been taken during dissection to prevent injury to vital structures (Figure 3 & 4). Final pathology report revealed lymphangioma with characteristics of fibrocollagenous tissue with cystically dilated spaces lined by flattened endothelium (Figure 5)

Postoperative period was uneventful and she was discharged from the hospital on postoperative day 5. Suture removal was done on postoperative day 7 and there was no swelling (Figure 6). Patient had symptoms of neuropraxia of Greater auricular nerve with symptoms of loss of sensation over outer surface of right ear & parotid region for up to 3 months due to manipulation of the nerve during surgery. Patient was followed up for 6 months. No recurrence was noted.

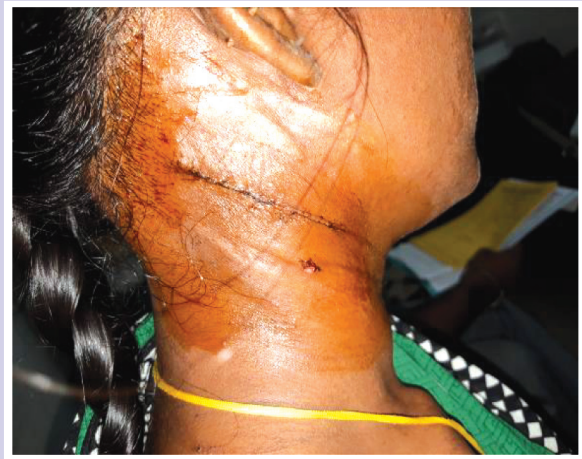

Figure 6: Post op day 7 after suture removal.

DISCUSSION

Lymphangiomas are lymphatic malformations that occur most commonly in children near the head and neck region. 65% of lymphangiomas are present at birth, and up to 85% are seen by second year of age. Some authors call them as cystic hygroma.^[5] Embryologically these lesions are believed to originate from sequestration of lymphatic tissue from lymphatic sacs, during the development of lymphatic- venous sacs.

These lymphatics fail to connect in the normal way to the venous channels. As a result, there are large fluid-filled spaces occupying the tissues and expanding tissue planes.^[6] In adults, lymphangiomas may occur due to infection, trauma, neoplasm, or iatrogenic injuries.^[7] Initial presentation is very rare in adult but few cases have been reported. The sites of predilection of these lesions are in the posterior triangle of the neck, axilla, mediastinum, groin, retroperitoneal space and pelvis in descending order.^[8]

These benign lymphatic lesions can be divided into three types: capillary, cavernous and cystic. Capillary or simple lymphangiomas are comprised of capillary-like lymphatic vasculature and are usually asymptomatic. Cavernous lymphangiomas are composed of dilated lymphatic channels and typically occur in the tongue, cheeks and lips, causing diffuse swelling. Cystic hygromas are histologically similar to cavernous lymphangiomas but in cystic hygromas, there are larger cystic masses which may communicate or be isolated.

Most lymphangiomas are asymptomatic and

enlarges progressively. They occur equally in males and females. The mass is soft, non-tender, and ill-defined with no local raise of temperature. Symptoms may develop when it enlarges and compresses the surrounding tissue due to bleeding or infection. Compression symptoms like dysphagia, dysphonia are present. Imaging techniques like Ultrasonography(USG) and computed tomography (CT) scanning and fine needle aspiration and cytology (FNAC) have been used to figure out the anatomy and pathology of lymphangiomas.^[9]

If the cystic hygroma is small and is cosmetically and functionally acceptable, no treatment other than observation will be required and those with obstructive symptoms complete surgical excision is the preferred treatment. It can be done under general or local anaesthesia.

Complications of the surgery include wound infection, bleeding, hematoma, postoperative seromas and injury to the vital structures. Complete excision of a cystic hygroma has been shown to have an 81% cure rate. When only part of the lymphatic malformation is excised, there is an 88% recurrence rate.^[10,11]

Macrocytic disease is treatable with aspiration and the instillation of sclerosant. Sclerosing agents used are picibannil OK-432, alcohol, bleomycin, ethanolamine oleate and trichloroacetic acid.^[12] In a trial with OK-432, 13 group of patients received four doses of the material at six to eight week intervals. There was a successful outcome in 86 percent of the cases, predominantly for macrocytic disease.

CONCLUSION

Lymphangioma of neck even rare in adult should be included in the differential diagnosis of neck swellings. The gold standard diagnosis is by histopathological evaluation. A complete surgical excision is usually curative in adults where there are low chances of recurrence.

CONFLICT OF INTEREST :

The authors declared no conflict of interest.

FUNDING : None

REFERENCES

1. Rolekar NG, Shah DK. Recurrent cystic lymphangioma of the neck in an adult: A case report of rare entity. *Int J Med Sci Public Health*. 2014; 3:243-245.
2. Charabi B, Bretlau P, Bille M, Holmelund M. Cystic hygroma of the head and neck? a long-term follow-up of 44 cases. *Acta Otolaryngol Suppl*. 2000; 543: 248-250.
3. Baer S, Davis J. Cystic hygroma presenting in adulthood. *J Laryngol Otol*. 1989; 103:976-977.
4. Schefter RP, Olsen KD, Gaffey TA. Cervical lymphangioma in the adult. *Otolaryngol Head Neck Surg*. 1985; 93:65-69.
5. Wernher A. Die angeborenen Zysten-Hygrome und die ihnen verwandten Geschwulste. In: *Anatomischer, Diagnostischer und Therapeutischer Beziehung*. Geissen: GF Heyer. 1843:76.
6. Sabin FR. The lymphatic system in human embryos, with a consideration of the morphology of the system as a whole. *Am J Anat*. 1909; 9:43-91.
7. Aneeshkumar MK, Kale S, Kabbani M, David VC. Cystic lymphangioma in adults: can trauma be the trigger? *Eur Arch Otorhinolaryngol*. 2005; 262(4):335-337.
8. Karmody CS, Fortson JK, Calcaterra VE. Lymphangiomas of the head and neck in adults. *Otolaryngol Head Neck Surg*. 1982; 90(3 pt1):283-288.
9. Machado LE, Osborne NG, Bonilla-Musoles F. Three-dimensional sonographic diagnosis of a large cystic neck lymphangioma. *Ultrasound Med*. 2004; 23(6):877-881.
10. Ricciardelli EJ, Richardson MA. Cervicofacial cystic hygroma. Patterns of recurrence and management of the difficult case. *Arch Otolaryngol Head Neck Surg*. 1991; 117(5):546-553.
11. Rolekar NG, Shah DK. Recurrent cystic lymphangioma of the neck in an adult: A case report of rare entity. *Int J Med Sci Public Health*. 2014; 3:243-245.
12. Kim KH, Sung MW, Roh JC, Han MH. Sclerotherapy for congenital lesions in the head and neck. *Otolaryngol Head Neck Surg*. 2004; 131:307-16.
13. Giguere CM, Bauman NM, Sato Y, Burke DK, Greinwald JH, Pransky S et al. Treatment of lymphangiomas with OK-432 (Picibanil) sclerotherapy: a prospective multi-institutional trial. *Arch Otolaryngol Head Neck Surg*. 2002; 128:1137-44.